

A prospective study of reconstructive procedures for post burn hand contractures

Nasr Hamid Naif Al-Qadasi

Department of General Surgery, Faculty of Medicine and Health sciences, Sana'a University, Yemen.

Abstract

Objective: The hand is among the most frequent sites of burns contracture deformity. It represents a common problem and a difficult challenge for many reconstructive surgeons. It is important to restore length, function, and provide good quality skin cover. Our aim is to evaluate the different surgical procedures for resurfacing after release of post burn hand contractures in terms of functional recovery and aesthetic outcome.

Methods: Totally 30 cases of post burn hand contractures were reconstructed between May 2018 and November 2019 according to site and type of contracture with individualization for each case. All cases were followed up with physiotherapy and splinting devices, functional and aesthetic outcome for each procedure.

Results were analyzed as per successful reconstruction, type of procedure, complications, functional and aesthetic outcome. Most of the cases can be resurfaced with skin grafting and few cases have clear indication for flap coverage which needs to be planned and executed cautiously. Z- plasties with proper planning gives maximum length gain with no donor morbidity as other procedures and acceptable appearance.

Conclusion: Postoperative physiotherapy and splinting are must for better outcome in all cases.

Key words: Burns, Hand, Finger, Web space, Contracture, Reconstruction, Graft, Flap, Physiotherapy.

Introduction:

The hand is the main interface between man and his environment. It is an organ of perception and expression [1]. Unfortunately; it is also the most vulnerable part of the body to be affected by burn injuries [2]. These injuries are unique and therefore categorized as major injuries by the American Burn Association, a categorization that emphasizes the importance of the hand not only to the burned individual but also to society as a whole [3]. Severely functionally limiting complications can follow deep thermal injury to the hand [4]. Post burn hand deformities, unlike others have a wide variety of presentations. The combinations of deformities can have bizarre presentations, especially when there is a flexion contracture of one joint and an extension contracture of

the adjacent joint [5]. Children particularly infants rolling into unprotected fires or exposed to hot liquids, home electrical current and explosions of poorly made stoves are the most common causes of burns in this age at our society. For adults especially females burns in the kitchen due to leak of gas from gas bottles or explosion of gas bottles, exposure to chemicals as in cleaners as well as electrical burns particularly in males are common causes. Management of post-burn hand deformities can be lengthy and complicated procedure. The mainstays of management of these contractures include complete surgical of scar tissue and resurfacing of the resultant soft tissue defect most commonly with split or full thickness skin grafts. If scar contracture release results in major exposure of the tendons or joints Z- plasties, local flaps, regional flaps,

Corresponding Author: Nasr Hamid Naif Al-Qadasi, Department of General Surgery, Faculty of Medicine and Health sciences, Sana'a University, Yemen.

island flaps and distant tissue transfer may be required. Appropriate choice of procedures and timing of surgery followed by supervised early physiotherapy and rehabilitative modalities are essential to prevent initial contracture formation and recontracture after surgical release [6]. The focus of the present study was to evaluate the different surgical procedures for reconstruction of post burn contractures of the hand in terms of functional and aesthetic outcome.

Patients and methods:

The present study included patients with post-burn hand contractures that was conducted over a period from May 2018 to November 2019. A total of 30 patients with post-burn hand contractures and age range was between eight months and 50 years with a mean age of 21.5 yr. Nineteen patients were females and eleven males. All patients are assessed clinically for site and type of contracture, range of motion and classified according to McCauley (7) into four severity grades table (1), but since Grade I & II were not managed surgically, they were not included in study. Trauma

Table (1): McCauley's severity grades

Grade I	Symptomatic tightness but no limitation in range of motion, normal architecture
Grade II	Mild decrease in range of motion without significant impact on activities of daily living, no distortion of normal architecture
Grade III	Functional deficit noted, with early changes in normal architecture of hand
Grade IV	loss of hand function with significant distortion of normal architecture of the hand
Subset classification for grade III & grade IV contracture: A: Flexion contractures B: Extension contractures C: Combination of flexion and extension contractures.	

All patients underwent a variety of surgical procedures, patients with hand contracture with supple skin on both of hand was corrected with Z-plasties. For contractures where Z-plasty or local advancement was not possible, the

contracture is released by fish tail incision with or without release of volar plate in inter phalangeal joints, collateral ligaments & / or joint capsulotomy, if the wound bed is good for graft take then split thickness or full thickness skin graft is done with internal fixation using K-wire. If vital structures (bone, joint, tendon) are exposed after contracture release, loco-regional or distant flaps are done. K-wires removed after 3 weeks, sometimes external splints are used if any problem with K-wires. Physiotherapy is started as soon as possible. Scar control measures such as pressure garment, silicon sheet and ointment were started after three weeks, once healing of graft / flap were ensured. Patients are followed up weekly for two weeks, two weekly for one month and monthly thereafter. Functional outcome scaled as good if there is improvement more than 75% of normal range for that joint. It is graded poor if improvement less than 50% of normal range. In between these two are graded average recovery. Aesthetic acceptance by the patient is questioned subjectively.

Results:

The present study prospectively analyzed 30 patients with post burn contracture of the digits, Web space, and hand who were treated in the center of Burns & Plastic Surgery. Out of 30 patients, 3 cases were operated for contracture of both hands. Table (2) shows classification of burn contractures based on McCauley's severity grade.

Table (2): classification of burn contractures based on McCauley's severity grade.

McCauley's grade	No. of Hands	Percentage %
Grade III A	14	46.7
Grade III B	3	10
Grade III C	4	13.3
Grade IV A	3	10
Grade IV B	3	10
Grade IV C	3	10
Total	30	100

None of the cases in the study belonged to grade I or grade II. Table (3) shows classification of burn contracture according to the site.

Table (3): classification of post burn hand contractures according to the site of contracture.

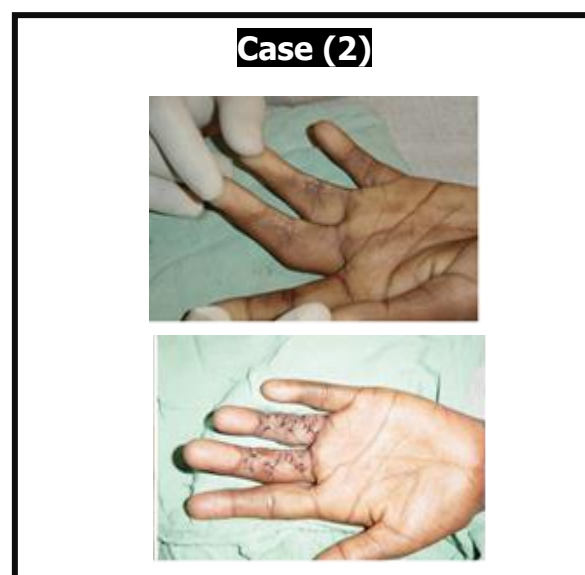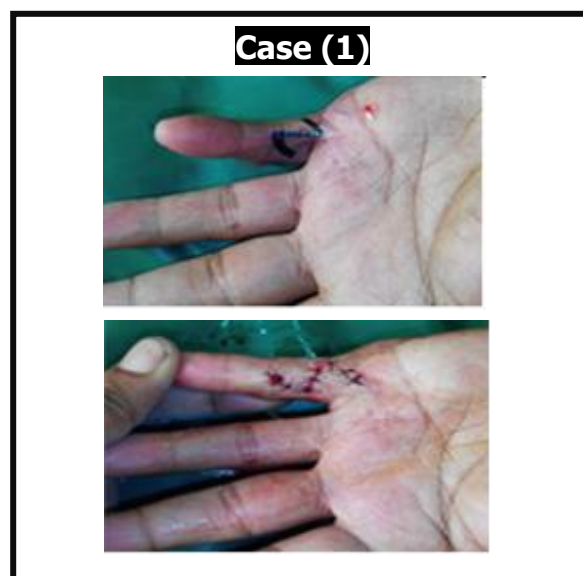
Site of contracture	No. of Cases	Percentage %
Volar surface of index, middle, ring and little fingers	18	60
Volar surface of thumb	3	10
Dorsal surface of thumb	1	3.3
Dorsum of Hand	2	6.7
Palm surface of hand	2	6.7
Volar surface of the wrist	1	3.3
Dorsum surface of the wrist	3	10
Total	30	100

The operative procedure was chosen according to the type and severity of hand contracture, size of the defect after contracture release structures exposed after release of contracture and condition of the surrounding skin. The various reconstructive procedures used for resurfacing after hand contracture release in the study were shown in table (4).

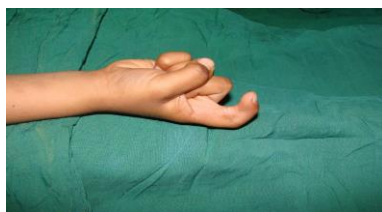Table (4): Resurfacing procedures done following contracture release in the study

Surgical procedure	Number of procedures
STSG	7
FTSG	14
Z-plasties	4
Local transposition flap	2
Radial for arm flap	1
Abdominal flap	1
Groin flap	1
Total	30

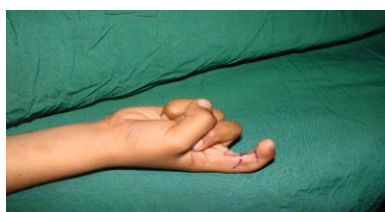K wire was used in 23 procedures, external splints in the form of POP slab or thermostatic splints were used following 7 procedures. Functional recovery of joint mobility was assessed for 6 months after surgery. Overall functional improvement in the study was satisfactory with good recovery after 19 (63.4%) resurfacing procedures, average recovery in 7 (23.3%) procedures, and poor recovery in only 4 (13.3%) procedures mainly with STSG procedures. In general, the complications were minimal and the aesthetic results were acceptable to majority of patients.



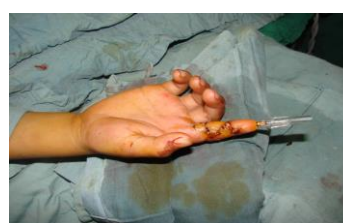Case (3)



A) post-burn contracture of Rt index volar surface.

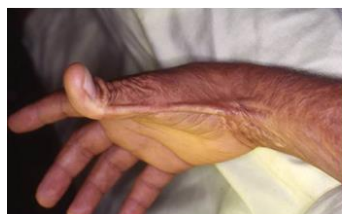

B) Released with four flap Z-plasty.

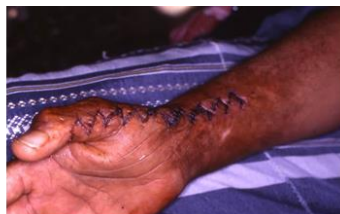

C) Stabilized with wire fixation.

Case (4)

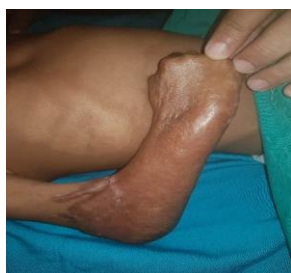

A) post-burn scar contracture for Rt distal arm, wrist and thumb.

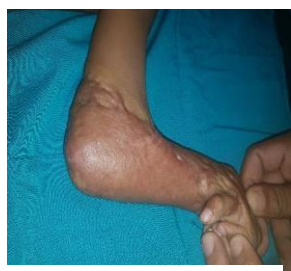

B) managed by release with multiple Z-plasty.

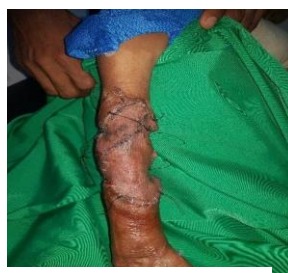Case (5)



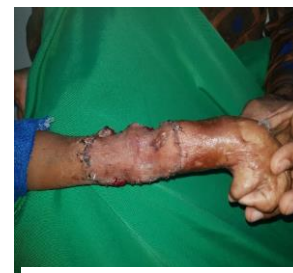A) post-burn contracted right hand & elbow.



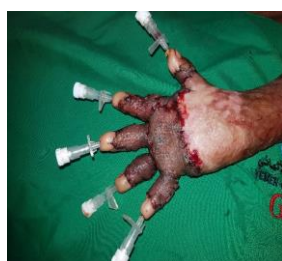B) post-burn contracted left hand & elbow.



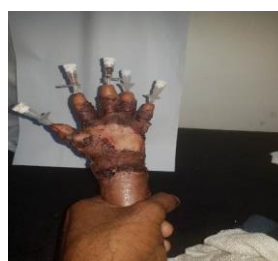C) Release of right elbow with STSG.



D) Release of left elbow with STSG.

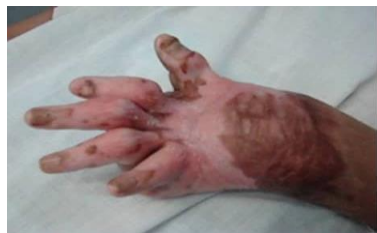

E) Rt hand after release and coverage with STSG and wire fixation.

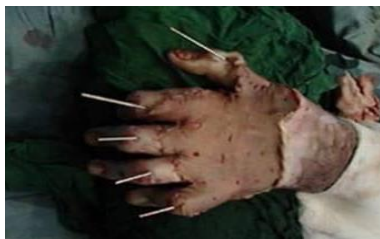

F) Lt hand after release and coverage with STSG and wire fixation.

Case (6)

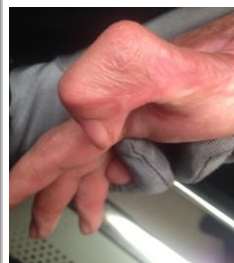

A) post-burn scar contracture of dorsal hand and fingers.

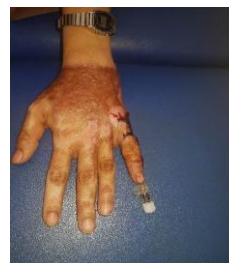

B) After contracture release and coverage by STSG with K-wires fixation.

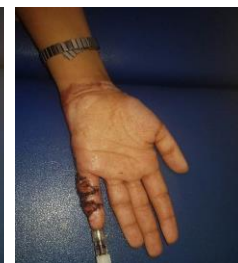Case (7)



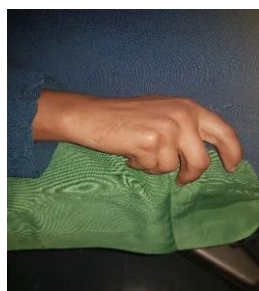A) Contracture of left little finger volar surface.



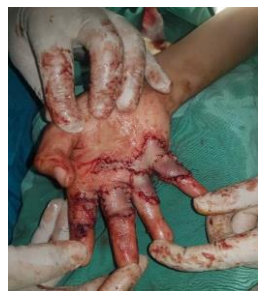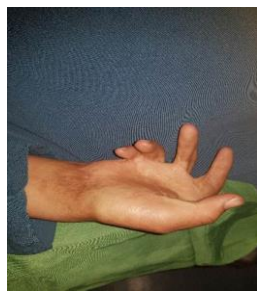B & C) Contracture release with FTSG coverage and wire fixation.



Case (8)

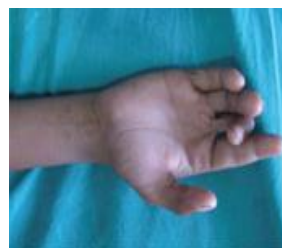

A & B) Rt post-burn contracture of volar surface of index to little fingers.

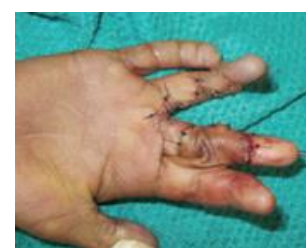

C) release of contractures and coverage by FTSG.

Case (9)

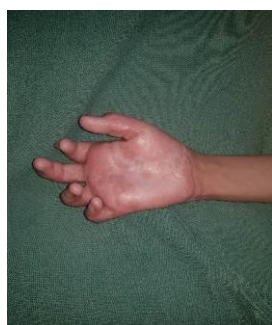

A) Post-electrical burn right middle and ring finger.

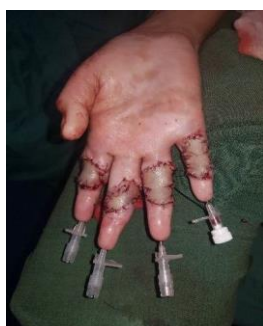

B) Release for ring finger by multiple Z-plasty & middle finger released & resurface by cross finger flap from dorsum of index finger.

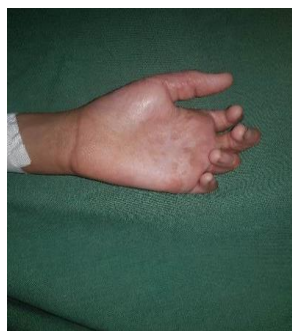Case (10)



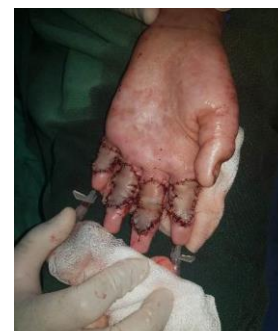A) Rt post-burn contracture of volar surface of index to little fingers.



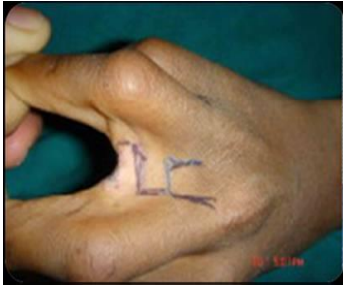B) release of contractures and coverage by FTSG with wire fixation.



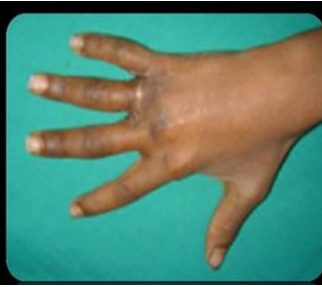C) Lt post-burn contracture of volar surface of index to little fingers.



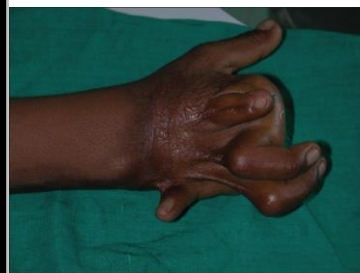D) Release of contractures and coverage by FTSG with wire fixation.

Case (11)

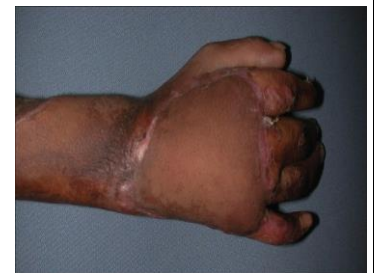A) Post burn contracture of 2nd to 4th web spaces.



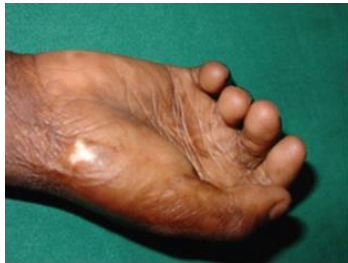B) Post release of contracture with coverage by square flaps.

Case (12)

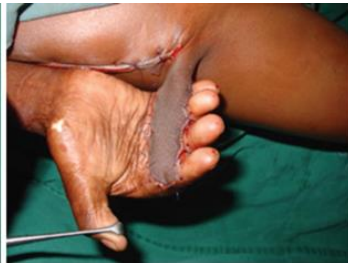A) Severe Rt dorsal hand contracture.



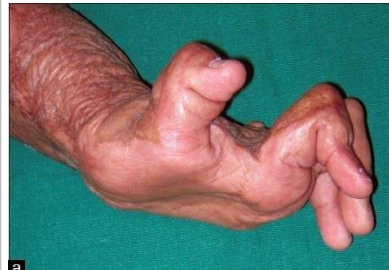B) contracture release is done and covered with distally based radial forearm flap.

Case (13)

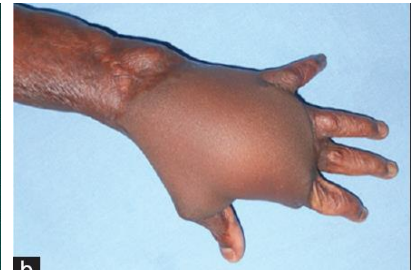A) Post-burn contracture of volar aspect of Rt index to little fingers.



B) Release is done and resurfaced with Groin flap.

Case (14)

A) Severe dorsal contracture of the Lt hand.



B) After release, the dorsal hand resurfaced with abdominal flap.

Discussion:

The hands account for less than 5% of TBSA (2), but loss of the hand constitutes a 57% loss of function for the whole person [8,9]. Whether the burned hand is an isolated injury or part of a large total body surface area burn, its loss represents a major functional impairment [10]. Treatment of the hands receives high priority because the patient's ability to perform useful work after recovery is to a great degree determined by residual hand function. The functional importance of the hand cannot be overemphasized in as much as severe hand burns may leave individuals unable to work or even care for themselves [5]. Post-burn contractures are common and severe in developing countries as our society and are a

significant problem in developed countries as well [3].

Hands are involved in more than 80% of all severe burns [11]. First degree and superficial second degree burns typically heal satisfactorily within about two weeks and have good functional and aesthetic results. Deep second degree and third degree burns with or without involvement of underlying structures predictably heal by scar tissue formation [2]. As a result at the time of acute management, deep burns can be resurfaced with skin grafts or skin substitutes to hasten wound healing, facilitate early motion and minimizes contracture formation [12]. At the time of initial treatment, the hand should be splinted in a functional position. A supervised passive motion protocol should be initiated by a hand

therapist as soon as possible after injury and within first two weeks of acute surgical management. At this subacute phase, patient should also be fit for pressure garments and silicon sheets. These therapies decrease scar formation through a pressure effect and a state of relative tissue hypoxia [13]. Once functionality limiting contractures have developed, little non-surgical treatment can be offered to reverse the scarring process. As a result, efforts to minimize contracture development are of great importance [2]. The classic rule of burn surgery is to delay secondary procedures until scar have fully matured, which takes approximately one year because of the possibility of recurrence [14], whereas other authors advice to operate earlier [15-17]. Green height et al. have shown that early release is not associated with a worse outcome and argues that, waiting for maturation of the scar is not necessary [18]. Surgical intervention may be indicated before the scar has fully matured in cases of severe skin contracture with limitation of motion, to prevent secondary tendon and joint contractures. Watson emphasizes that it is important to focus the reconstructive efforts on what the patient desires and requires and not to attempt an over-optimistic goal of normal form and function [19]. Regarding the operative strategy, evaluation of the deformity in each of the components of skin, tendons, joints and bones was done while making the treatment plan. When a hand is severely involved, choose procedures that will bring the maximum benefit to the patient at each operative session [20]. Kucan and Bash stress that the well described reconstructive ladder should be followed, choosing the simplest method that will achieve the reconstructive goals [15]. In order of increasing complexity, the relevant reconstructive methods are Z-plasty, skin grafts, local flaps, regional flaps, distant flaps, free flaps and cross limb flaps. Good surgical judgment and a sound knowledge of the available flaps are needed to identify and successfully treat those hands that will benefit from flap coverage.

Conclusion:

In surgical management of post burn hand deformities,

whenever applicable Z plasties and their modification gives best functional and aesthetic outcome, otherwise most of the defects can be covered with skin grafts. Needless to say strict postoperative regimen of physiotherapy and splinting are a must for optimum outcome. In patient requiring flap, proper selection of flap depending on defect, availability of donor area and surgeon expertise are a prerequisite for optimum outcome.

References:

1. Robson M.C., Smith D.J., Vander Zee A.J. et al. Making the burned hand functional. *Clinics Plast Surg*, 1992;19:663.
2. Kurtzman LC, Stern PJ. Upper extremity burn contractures. *Hand Clinics*, 1990;6:261-79.
3. Nelson D.L. The importance of the physical examination. *Hand Clinics*, 1997;135:13.
4. Fufa DT, Chuang ss, Yang JY. Post burn contractures of the hand. *J Hand Surgery* 2014;39(9):1869-76.
5. Gkalanl., Zgüf., Gürsu G., kecik A. Factors affecting results in thermal hand burns. *Annals of Burns and Fire disasters* 1996;9:222-8.
6. Sabapathy SR, Bajantri B, Bharathi RR. Management of post burn hand deformities. *Indian J Plastic Surgery*, 2010;43 (3):72-79.
7. Mecauley RL. Reconstruction of the pediatric burned hand. *Hand Clin* 2000;16:249-59.
8. American Medical Association: Guides to the evaluation of permanent impairment, 4th ed. Chicago: American Medical Association: Guides to the evaluation of permanent impairment, 4th ed. Chicago: American Medical Association, 1994.
9. Engrav LH, Dutcher KA, Nakamura DY. Rating burn impairment. *Clin Plast Surg*. 1992;19:569-98.
10. Malachy EA, Robert L. Mécauleyeditor. *Functional and Aesthetic Reconstruction of Burned Patient*: Boca Raton; 2005.
11. Pruitt BA, Dowling JA, Moncrief JA. Escharotomy in early burn care. *Arch Surg* 1968;96:502-7.

12. Stern PJ, Yakuboff KP, Burn Contractures In: Chapman MW. Editor. Chapman's Orthopedic Surgery. 3rd ed. Philadelphia, Lippincott Williams & Wilkins; 2011.
13. Kregmerman PA, Andres LA, Lucas HD, Silvermann AL, Smith AA, Reconstruction of burned hand. Plastic Reconstructive Surgery 2011;127 (2):752-59.
14. Achauer BM, VanderKam VM. Burn reconstruction. In: Achauer BM, Plastic Surgery: Indications, Operations, and Outcomes, Vol 1. St. Louis: Mosby; 2000.
15. Kucan JO, Bash D. Reconstruction of the burned foot. Clin Plast Surg 1992;19:705-19.
16. Schwarz RJ, Joshi KD. Treatment of post-burn contractures. J Nephrol Med Assoc. 2004;43:211-17.
17. Baux S, Mimoun M, Kirsch JM, Zumer L, Berard V. Treatment of elbow contractures in burns. Burns Int Therm Inj. 1987;13:241-44.
18. Greenhalgh DG, Gaboury T, Warden GD. The early release of axillary contractures in pediatric patients with burns. J Burn Care Rehabil 1993;14:39-42.
19. Watson S. Hand burns. Repair Reconstr. 2001;2:2-4.
20. Salisbury RE. Reconstruction of the burned hand. Clin Plast Surg. 2000;27:65-69.